

# Application of Ligation of Ascending Branch of Uterine Artery Combined with Ligation of the Utero-Ovarian Artery Anastomoses for Hemostasis in Cesarean Section

Shuang Hu<sup>1</sup>, Liu QingLong<sup>1</sup>, Li Xia<sup>1\*</sup>, Jinxiao Lin<sup>1</sup>, and Yongjin Xie<sup>2,3</sup>

<sup>1</sup>Fujian Maternity and Child Health Hospital College of Clinical Medicine for Obstetrics & Gynecology and Pediatrics, Fujian Medical University, China

<sup>2</sup>Fujian Clinical Research Center for Maternal-Fetal Medicine, China

<sup>3</sup>National Key Obstetric Clinical Specialty Construction Institution of China, China

## \*Corresponding author

Li Xia, Fujian Maternity and Child Health Hospital College of Clinical Medicine for Obstetrics & Gynecology and Pediatrics, Fujian Medical University, China.

Received: March 31, 2026; Accepted: April 08, 2026; Published: April 16, 2026

## ABSTRACT

**Background:** Postpartum hemorrhage is a life-threatening pregnancy complication, which is still the main preventable cause of high morbidity and mortality in pregnant women. During cesarean section, lower uterine segment hemorrhage is an important cause of postpartum hemorrhage. We aim to evaluate the efficacy and safety of the application of "ligation of the ascending branch of uterine artery combined with ligation of the utero-ovarian artery anastomoses" for hemostasis during cesarean section.

**Methods:** 47 patients admitted to the Second Department of Obstetrics and Maternity of Fujian Maternal and Child Care Service Center from March 2018 to March 2022 were collected. There were 11 cases of placenta previa with placenta implantation and scar uterus. Placenta previa with placenta implantation in 3 cases; Placenta previa combined with twin in 1 case; Placenta previa with scar uterus in 12 cases; Placenta previa in 3 cases; Placenta implantation complicated with severe preeclampsia and scar uterus in 1 case; Placenta implantation with scar uterus in 1 case; Placental implantation in 2 cases; 1 case of twin with uterine myoma and 1 case with cicatricial uterus; 1 case of twin with severe preeclampsia; There were 2 simple twins; Breech in 1 case; Placental abruption: 1 case; Uterine fibroids in 3 cases; Scar uterus: 3 cases. In all cases, intravenous injection of 100 micrograms of carbetin was routinely used to promote uterine contraction after delivery of the fetus. For those who still had diffuse bleeding in the lower segment of the uterus after ligation of the ascending branch of the uterine artery, combined suture was performed to ligate the the utero-ovarian artery anastomoses, and the short- and long-term prognosis, uterine were analyzed.

**Results:** All 47 patients were successfully hemostatic and no hysterectomy was performed.

**Conclusions:** Ligation of the ascending branch of uterine artery combined with ligation of the utero-ovarian artery anastomoses is one of the fast, safe, effective and feasible hemostasis methods in cesarean section. The combination of the latter can block the uterine blood flow and further reduce the amount of intraoperative bleeding, especially for uterine body bleeding, which can be more rapid and effective hemostasis.

**Keywords:** Postpartum Hemorrhage, Ligation of the Ascending Branch of Uterine Artery, Ligation of the Communicating Branch of Utero-Ovarian Artery, Combined Suture and Ligation

Postpartum hemorrhage is traditionally defined as more than 500 ml after vaginal delivery or more than 1000 ml after cesarean section. Recently, postpartum hemorrhage has been redefined

as a cumulative blood loss of 1000 ml or more after delivery, which is related to hypovolemic symptoms or signs, but not to the way of delivery [1]. Postpartum hemorrhage remains the leading preventable cause of maternal disease and death worldwide [2,3]. Globally, postpartum hemorrhage accounts for 8% of the causes of maternal death in developed area, and 20% in developing areas [3]. The rate of cesarean section in China

**Citation:** Shuang Hu, Liu QingLong, Li Xia, Jinxiao Lin, Yongjin Xie. Application of Ligation of Ascending Branch of Uterine Artery Combined with Ligation of the Utero-Ovarian Artery Anastomoses for Hemostasis in Cesarean Section. Open Access J Gyneco Obstet Res. 2026. 4(2): 1-7.

DOI: doi.org/10.61440/JGOR.2026.v4.69

is significantly higher than before, although the equipment and technology have been improved accordingly, the number of cases of massive hemorrhage in cesarean section has increased. Therefore, it is particularly important to improve the alarm rate during operation, deal with intraoperative and postoperative bleeding timely and effectively, and make great efforts to preserve the uterus, which is the key to reduce maternal mortality and maintain their physical and mental health. Uterine atony is the most common cause of postpartum bleeding, placenta previa, placental adhesion, placental accreta, placental penetration, chorioamnionitis, therapeutic use of magnesium sulfate, long-term labor or emergency labor, induced or increased labor, uterine leiomyoma, uterine swelling caused by multiple pregnancy, giant fetus, polyhydramnios and so on are closely related to it. Cesarean section has a higher risk of postpartum hemorrhage than vaginal delivery [4]. Older parturients and extreme parity (0 and >4) are also risk factors. Severe preeclampsia and eclampsia, HELLP (hemolysis, elevated liver enzyme levels and low platelet count) syndrome, intrauterine fetal death, placental abruption or acquired coagulation dysfunction (such as amniotic fluid embolism) or hereditary complications can cause maternal coagulation dysfunction, which can lead to massive bleeding during and after operation [4]. For intraoperative bleeding, conservative treatment should be considered first. When conservative measures such as drug treatment, uterine compression or packing can not control bleeding, surgical methods can save lives [4]. Ligation of bilateral ascending branches of uterine artery is a feasible scheme in cesarean section. It can effectively and quickly stop the bleeding. At the same time, combined with bilateral utero-ovarian artery anastomoses ligation will more effectively reduce the amount of blood loss [4]. When intraoperative bleeding is ferocious, it is difficult to effectively stop bleeding and may endanger the lives of pregnant women, total hysterectomy should be considered to save maternal lives, and the effect is accurate, but the pregnant women lose their ability to reproduce after hysterectomy and suffer serious psychological trauma.

## Methods

### General Information

A retrospective analysis of 47 patients admitted to the Second Department of Obstetrics and Maternity of Fujian Maternal and Child Care Service Center from March 2018 to March 2022 is shown in Table 1. Inclusion criteria: in accordance with the indication of cesarean section. Exclusion criteria: patients with blood coagulation disorders, patients with blood diseases, immune system diseases, complicated with cardiac insufficiency, liver and kidney function damage, malignant tumors and other surgical contraindications. Cognitive impairment, history of mental illness. The method of “ligation of the ascending branch of uterine artery combined with ligation of communicating branches of utero-ovarian artery” was used because of poor uterine contraction and bleeding during cesarean section. The application of this technology was approved by the Ethics Committee of Fujian Maternal and Child Care Service Center, and all patients and/or their close relatives signed a written informed consent before surgery.

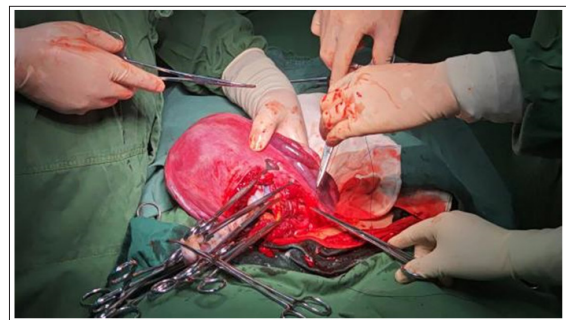
### Preoperative Preparation and Examination

All patients were routinely examined for blood routine, blood coagulation, biochemical test, AIDS, syphilis, hepatitis B,

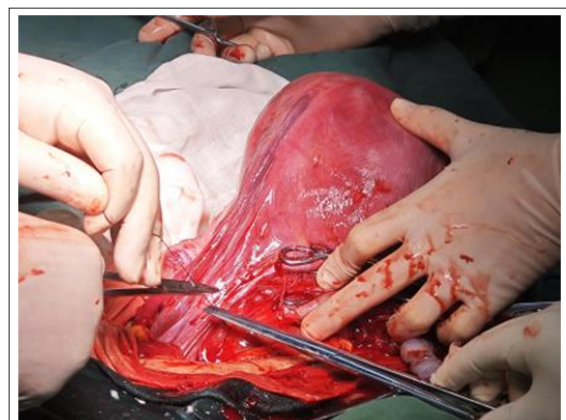hepatitis C and other auxiliary examinations before operation, as well as obstetrical level I Doppler ultrasound and fetal heart monitoring to understand the general situation of pregnant women and fetuses before operation.

### Mode of Operation

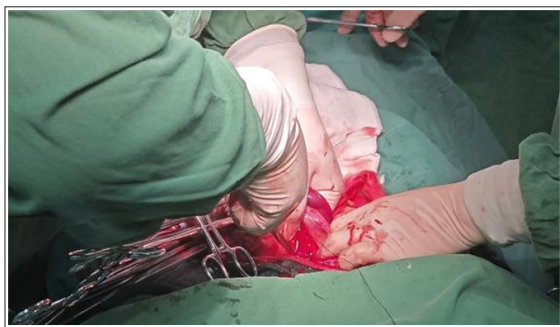The cesarean section was performed by the same surgical team. Ligation of ascending branch of uterine artery combined with ligation of the utero-ovarian artery anastomoses is the preferred method. During the operation, the pregnant women stretched her limbs with the word “ten” and lay on her back on the stage. During the operation, autologous blood was recovered, filtered and re-infused, and the one-time cushion under the buttocks was collected to calculate the amount of vaginal bleeding. A transverse or longitudinal incision was taken in the middle of the patient’s lower abdomen. For patients with placenta previa, determine the placental attachment range and placental position again, touch the weak placenta, and choose the cesarean section incision to avoid the anterior placenta as much as possible. Ligation of the ascending branches of the uterine artery: after the delivery of the placenta (in the case of placenta accreta, before the delivery of the placenta), lift the uterus out of the abdominal incision and touch the internal orifice of the cervix in the uterine cavity, taking its level as an indicated point, push the bladder down to the level of the vaginal fornix, expose the upper part of the cervix and vagina, and use the synthetic thread of the uterus (with a large needle). Through the cervical muscular layer at 1-2cm on the medial side of the uterus, enter the needle from the back, pass through the muscular layer, bypass the blood vessel around the uterus from the outside, exit the needle from back to front in the vascularized area of the broad ligament, and ligate the blood vessels around the uterus, that is, the ascending branches of the uterine artery, as shown in figure 1-6.



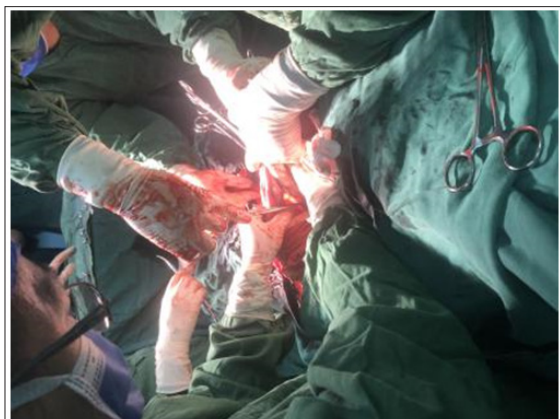**Figure 1:** Ligation of ascending branch of left uterine artery



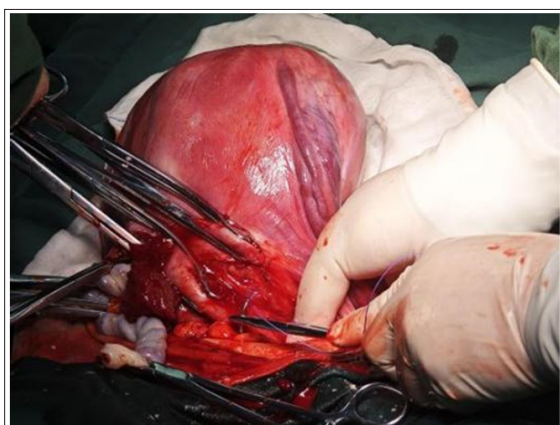
**Figure 2:** Ligation of ascending branch of right uterine artery



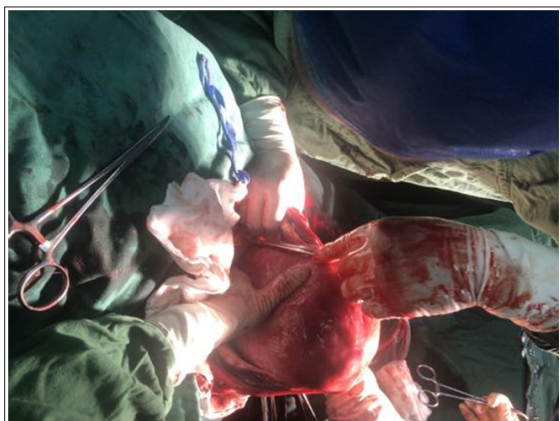
**Figure 3:** Anterior view of ligation of ascending branch of left uterine artery



**Figure 4:** Posterior view of ligation of ascending branch of left uterine artery

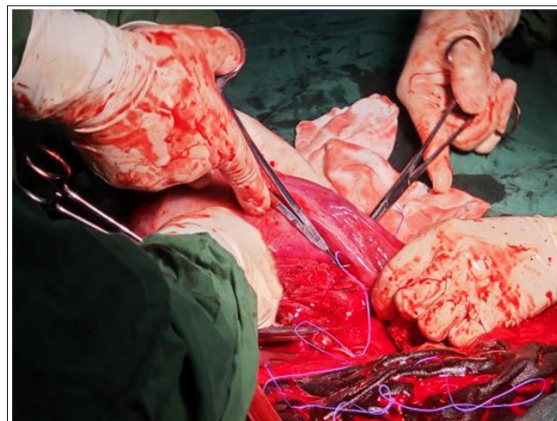


**Figure 5:** Anterior view of ligation of ascending branch of right uterine artery

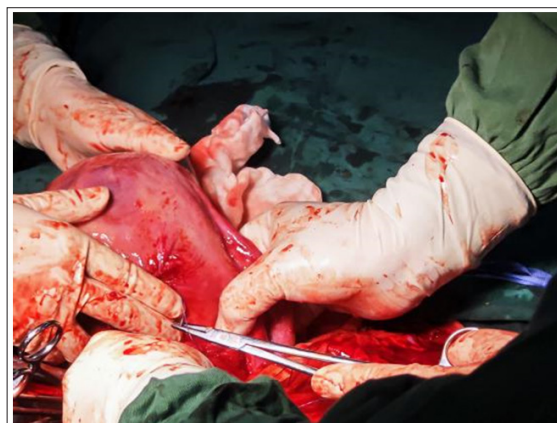

**Figure 6:** Posterior view of ligation of ascending branch of right uterine artery

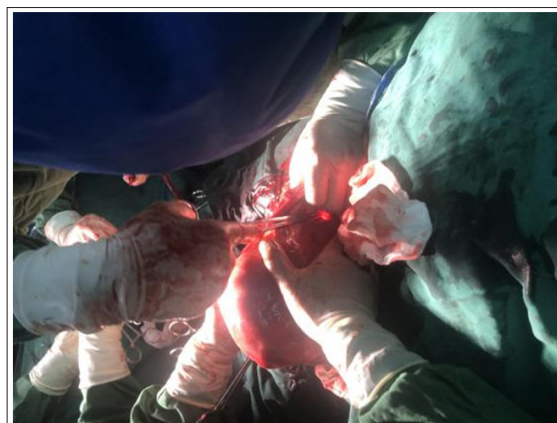The method of ligation of the utero-ovarian artery anastomoses: the needle was inserted into the non-vascularized area under the fallopian tube near the uterus, and the needle was placed above / below the inherent ligament of the ovary. The synthetic suture (with large needle) was also used to block the uterine blood flow from the communicating branches of the utero-ovarian artery, as shown in figure7-10.



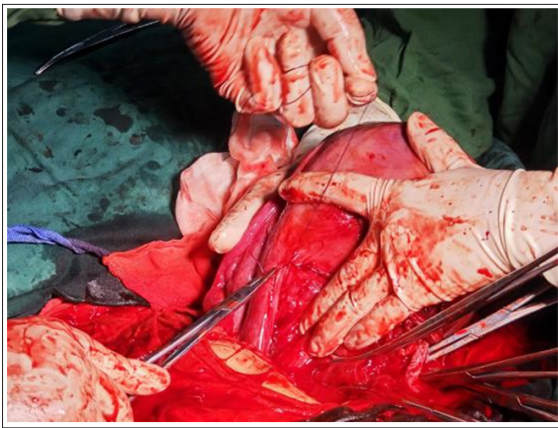
**Figure 7:** Anterior view of ligation of the communicating branch of left utero-ovarian artery



**Figure 8:** Anterior view of ligation of the communicating branch of right utero-ovarian artery



**Figure 9:** Posterior view of ligation of the communicating branch of right utero-ovarian artery



**Figure 10:** The ligation of the communicating branch of right utero-ovarian artery

Intraoperative supplementary hemostatic regimen: in all cases, 100  $\mu$ g of oxytocin was injected intravenously after fetal delivery to promote uterine contraction. The placenta was removed after bilateral ascending uterine artery ligation combined with the utero-ovarian artery anastomoses ligation, and there was generally no active bleeding. If there was still a small amount of blood oozing in the lower segment of the uterus, local suture with “8” suture, Hayman suture and “combined longitudinal suture of the lower segment of the uterus, namely King’s uterine suture”. When the bleeding can not be controlled and may endanger the life of the pregnant woman, do not consider keeping the uterus, hysterectomy should be performed immediately to save the maternal life.

Record the amount of blood loss during and 2 hours after operation, check the blood routine on the second day after operation, observe the general condition, the change of body temperature and uterine involution after operation, record the time of hospitalization after operation, give discharge guidance and telephone follow-up after discharge. The follow-up contents included the cleaning time of lochia, the time of menstruation recovery, uterine involution, neonatal prognosis and feeding, and second pregnancy. (Table 1)

### Statistical Methods

SPSS 26.0 software was used for statistical analysis. The data in accordance with the normal distribution is expressed as the mean  $\pm$  standard deviation,  $\chi$  values  $\pm$ s. The count data is represented by frequency and rate.

### Results

#### Clinical Characteristics of Patients

There were 47 patients, aged 33.1  $\pm$ 3.9 years, 2.8  $\pm$ 1.4 pregnancies, 0.9  $\pm$ 0.7 deliveries, and 30 cases (63.8%) had a history of cesarean section. The number of cesarean sections was 0.8  $\pm$ 0.7, preoperative hemoglobin 114  $\pm$ 10 g / L, intraoperative gestational age 36.6  $\pm$ 3.2 weeks (except 2 cases, induced labor due to fetal malformation at 25 weeks of pregnancy).

#### Intraoperative hemostasis

All of the 47 cases had got successful hemostasis during the operation, and no hysterectomy was performed. There were 11 cases of placenta previa with placenta accreta and scar uterus, 3

cases of placenta previa with placenta accreta, 1 case of placenta previa with twins, 12 cases of placenta previa with scar uterus, 3 cases of simple placenta previa, 1 case of placenta accreta with severe preeclampsia and scar uterus, 1 case of placenta accreta with scar uterus, 2 cases of simple placenta accreta and 1 case of twins complicated with uterine leiomyoma. There were 1 case of twins with cicatricial uterus, 1 case of twins with severe preeclampsia, 2 cases of simple twins, 1 case of breech presentation, 1 case of placental abruption, 3 cases of simple uterine leiomyoma and 3 cases of simple scar uterus.

Supplementary hemostatic regimen: 18 patients were treated with King’s uterine ligation (that is, ligation of the ascending branches of uterine artery combined with longitudinal uterine suture). Among them, 12 cases were placenta previa with placenta accreta, 4 cases were placenta previa, 1 case was scar uterus with placenta accreta, and 1 case was simple uterine scar. 9 patients underwent Hayman suture, including 3 cases of placenta previa with placenta accreta, 1 case of simple placenta previa, 3 cases of placenta accreta (including 1 case with severe preeclampsia) and 2 cases of twins (including 1 case with uterine leiomyoma).

The maximum intraoperative blood loss of 47 parturients was 3010 ml, and the least was 400 ml. The average intraoperative blood loss was 1122.2  $\pm$ 637.6 ml in patients with placenta accreta and 607  $\pm$ 480.4 ml in patients without placenta implantation. There were 10 patients with intraoperative blood loss greater than 1000 ml, 7 with placenta previa with placenta accreta, 1 with placenta accreta with macrosomia and 2 with placenta previa. Blood products were infused in 12 cases (25.5%).

#### Operation Time

Among the 47 cases, the shortest was 51 minutes and the longest was 157 minutes. The average operation time was 86.5  $\pm$ 25.8 minutes.

#### Short-term Postoperative Recovery

There were 29 patients with OICU (61.7%). None of the 47 patients had postpartum hemorrhage, delayed postpartum hemorrhage and puerperal infection. The postoperative hemoglobin level was 103  $\pm$ 15 g / L, and the postoperative hospital stay was 4.0  $\pm$ 1.9 days. There was no delayed postpartum hemorrhage at discharge.

#### Ultrasonic Follow-up Results

The 47 patients, 41 cases were followed up effectively and 6 cases lost follow-up. 34 patients were revisited 42 days after delivery, the uterine involution was good, no obvious abnormality was found in the rest, and the remaining 7 patients could not be returned to hospital in time for reexamination due to personal factors.

#### Long-term Prognosis

41 cases were followed up effectively, the longest follow-up time was 30 months, and the shortest time was 6 months. Bilateral tubal ligation was performed in 15 cases (31.9%), of which 1 case became pregnant again 2 years after operation, and her healthy baby was delivered by cesarean section at the 38 weeks plus 6 days of pregnancy. The cleaning time of maternal

lochia was 10+ -50+ days, and the time of menstrual recovery was 1-12 months. no pregnancy, menstrual blood retention, delayed postpartum hemorrhage, puerperal infection and other complications were found.

### Neonatal prognosis

Among the 47 parturients, 2 were fetal malformations and underwent cesarean section in the middle stage. The Apgar scores of the other 45 newborns at 1 minute, 5 minutes and 10 minutes after delivery were  $9.76 \pm 0.65$ ,  $9.96 \pm 0.30$  and  $9.96 \pm 0.30$ , respectively. The Apgar score was  $9.96 \pm 0.30$  at 10 minutes. 21 cases were transferred to the Department of Neonatal Pediatrics (46.7%), including 10 premature infants and 1 wet lung. The rest were transferred to Neonatal Pediatrics because of neonatal shortness of breath or dyspnea. After observation and improvement, there was no neonatal death. All newborns developed well during follow-up and did not die within six months after birth.

### Discuss

Postpartum hemorrhage (PPH) is a life-threatening pregnancy complication, which is still the main preventable cause of high morbidity and mortality in pregnant women. PPH accounts for 8 per cent of maternal mortality in developed countries and 20 per cent in developing countries [5]. The high-risk factors include previous history of PPH, macrosomia, previous cesarean section, maternal uterine fibroids, preeclampsia, multiple pregnancy, polyhydramnios, placental factors (history of placental residue, placental abruption, placental adhesion, placenta previa, placenta accreta, etc.), prolonged second stage of labor, perineotomy, etc. The causes and high-risk factors of PPH can be summarized as "Four T": Tone, Trauma, Tissue and Thrombin. Among them, uterine atony is the most common cause of PPH [6,7]. The uterine blood flow in the non-pregnant state is about 60 ml per minute, while the uterine blood flow in full-term pregnancy is about 600 ml per minute, which is 10 times that of the non-pregnant period, so the bleeding caused by uterine atony during cesarean section should be stopped more quickly and effectively to prevent further blood loss [8]. The control of postpartum hemorrhage depends largely on uterine contraction [9]. PPH seriously threatens the lives of pregnant women and is one of the common serious complications in obstetrics. Early identification and treatment of high-risk factors of postpartum hemorrhage can significantly reduce the incidence of postpartum hemorrhage [6].

When PPH occurs, the initial treatment is uterine massage, which induces uterine contraction by stimulating endogenous prostaglandins [4]. At the same time, RCOG recommends routine prophylactic use of oxytocin in all parturients during the third stage of labor because they reduce the risk of PPH. For patients undergoing cesarean section, there can be slow intravenous injection of oxytocin to promote uterine contraction and reduce blood loss [6]. If conservative treatment such as medicine and physical therapy can not effectively control bleeding, surgical intervention should be carried out as soon as possible, such as uterine gauze packing, uterine balloon packing, B-Lynch suture, "8" suture, uterine artery embolization, ligation of superior branch of uterine artery, ligation of iliac artery, total hysterectomy and so on. The Canadian Society of Obstetrics and Gynecology (SOGC) recommended ligation of the ascending

branch of the uterine artery as the first choice for surgical treatment of postpartum hemorrhage after conventional drug treatment was ineffective [10].

The uterine artery is formed by the anterior trunk branch of the internal iliac artery (also known as the inferior abdominal artery). It moves downward and forward along the pelvic lateral wall behind the peritoneum and reaches the lateral side of the uterus through the base of the broad ligament and the para-uterine tissue. The uterine artery straddles the ureter and divides into superior and inferior branches at the lateral edge of the uterus (about the 2 cm level of the internal orifice of the cervix). During term pregnancy, the lower segment of the uterus is fully formed, and the uterine artery is divided into upper and lower branches at the junction of the lower segment of the uterus [11]. The ascending branch of the uterine artery is thicker, and the ascending branch along the lateral wall of the uterus is the uterine body branch, which supplies the blood circulation of the uterine body and the fundus of the uterus. The uterine body branch is divided into three branches in the uterine horn, which are the uterine fundus branch, the fallopian tube branch and the ovarian branch (which coincides with the ovarian artery) [12,13]. The descending branch of the uterine artery is thinner, anastomoses with the blood vessels of the uterine iliac ligament, distributes in the cervix and the upper segment of the vagina, and supplies the blood circulation of the lower segment of the uterus, the cervix and the upper part of the vagina [14].

The ovarian artery originates from the abdominal aorta, runs behind the peritoneum along the psoas major muscle, goes outward and downward to the pelvic margin, passes through the lower segment of the ureter and common iliac artery, reaches the pelvic funnel ligament, crosses inward through the ligament, and then backward through the ovarian mesenter. branches enter the ovary through the ovarian door. Before entering the ovary, there are still branches of the ovarian artery in the mesosalpinx to supply the blood circulation of the fallopian tube. At the uterine angle, its terminal anastomoses with the ovarian branch of the ascending branch of the uterine artery [14].

The hemostatic mechanism of ascending branch of uterine artery combined with ligation of the utero-ovarian artery anastomoses may be: ligation of ascending branch of uterine artery blocks the main blood supply of uterus and slows down uterine blood flow. The ligation of the the utero-ovarian artery anastomoses further blocked the blood supply from the ovary, which further reduced the amount of bleeding during the operation and successfully stopped the bleeding. The key to successful operation is to fully separate and expose the surgical approach, including the adhesion of uterus, abdominal wall, intestine and omentum, as well as the adhesion of bladder and lower uterus. To sum up, ligation of ascending branch of uterine artery combined with ligation of communicating branch of ovarian uterine artery is a safe, rapid and effective method for hemostasis during cesarean section, especially for placenta previa, placenta accreta, uterine scar, twin pregnancy and diffuse bleeding in the lower uterine segment caused by difficulties in fetching fetal head. This operation can quickly stop bleeding, reduce intraoperative blood loss, avoid hysterectomy caused by postpartum hemorrhage, and retain the fertility of young women. This is indeed a valuable method of operation, at present, no long-term complications

have been found, so we need to continue to pay attention to the follow-up of maternal menstruation and pregnancy.

Uterine gauze packing can play the role of compression and hemostasis, but it is not ideal. For hemorrhage can not achieve a good hemostatic effect, higher technical requirements for the operator. The gauze has to be packed systematically from the inside to the outside, and extra effort should be made to completely and tightly pack the uterine cavity, leaving no dead space [15]. At the same time, this technology was not advocated for the treatment of hemodynamically unstable patients [15]. In contrast, intrauterine balloon packing can supplement the deficiency of gauze packing, and the effect is ideal. It is easy and can be rapidly inserted, and allowance for lochia continually flowing, decreased incidence of infections, and painless removal. Nonetheless, the high cost of the Bakri balloon limits its application in the primary hospitals of developing countries [15]. Simultaneously, with the development of intravascular interventional therapy, some researchers have tried to temporarily block uterine blood flow by placing balloon catheters in distal abdominal aorta, bilateral common iliac artery or internal iliac artery. By blocking the blood flow, reducing bleeding, and the wound is clear, not disturbed by bleeding, making it easier for the operator to repair, stop bleeding and other surgical operations. The rich anastomosis of internal iliac artery and external iliac artery makes the placement of iliac artery balloon ineffective [16]. Suturing the internal iliac artery can also stop bleeding, but the operation is complex, requires high experience and technical requirements of the operator, and is easy to damage the ureter during the operation. Uterine artery embolization can quickly and effectively block uterine blood flow, reduce uterine bleeding and achieve a good hemostatic effect. The operation time is shorter than that of uterine artery ligation and B-Lynch suture. However, a highly qualified operator and appropriate equipment are required to perform uterine artery embolization. The failure to control hemorrhage could result in repeated embolization attempts, increasing the risk of vessel perforation, arterial hematoma, and pelvic infection [17,18]. Meanwhile, when the situation during the operation is dangerous, it may be difficult for the operator to recall the operation steps completely and fail to reduce bleeding quickly and effectively and save lives. On the other hand, the method of ligation of ascending branch of uterine artery is simple and easy to operate, and can directly block most of the uterine blood supply, and the hemostasis is firm and rapid, and it is not easy to damage and transfusion.

Moreover, combined with the ligation of the utero-ovarian artery anastomoses, block the blood supply of the utero-ovarian artery, shorten the operation time, and further reduce the amount of intraoperative bleeding. Ligation of ascending branch of uterine artery combined with ligation of communicating branches of the utero-ovarian artery was carried out before uterine suture, and the hemostatic effect of operation was observed directly, and the success rate was high. It is especially suitable for extensive bleeding in the lower segment of the uterus caused by uterine atony with good hemostatic effect.

All the 47 patients were treated with ligation of ascending branch of uterine artery combined with ligation of the utero-ovarian artery anastomoses to prevent postpartum hemorrhage

and to avoid emergency hysterectomy which for saving maternal life. It avoids the related operative complications after hysterectomy and the psychological trauma of loss of re-fertility. The effective follow-up cases recovered well, and there were no complications such as uterine adhesion, irregular menstruation and lower menstrual pain. Postoperative follow-up gynecological examination and uterine ultrasound showed no uterine and pelvic abnormalities. Ligation of ascending branch of uterine artery combined with ligation of communicating branch of utero-ovarian artery was applied to enucleation of uterine fibroids after cesarean section in 4 cases. Uterine fibroids, which are the most common pelvic tumors in women, their blood supply almost exclusively originate from the uterine artery [11]. This operation was performed before myomectomy, which not only reduced intraoperative hemorrhage, but also shortened operation time [19]. It is an effective method to reduce the clinical recurrence rate and improve the success rate of intraoperative hemostasis [20]. Ligation of ascending branch of uterine artery combined with ligation of communicating branch of ovarian uterine artery is used in the diagnosis and treatment of bleeding during cesarean section, especially in the diagnosis and treatment of intraoperative bleeding caused by lower uterine bleeding, poor uterine contraction and wide uterine cavity caused by poor conservative treatment. Patients with placenta accreta have more bleeding during cesarean section and high risk of operation. The combination of suture and ligation can stop bleeding quickly and effectively, reduce the amount of blood loss during operation, and make the operation stop bleeding successfully. However, when the pelvic adhesion is severe, the uterus can not be held out of the abdominal cavity, it is difficult to fully expose the posterior wall of the uterus, and the ligation of the superior branch of the uterine artery cannot be performed, so the hemostatic scheme should be individualized.

## Conclusions

Ligation of the ascending branch of uterine artery combined with ligation of the utero-ovarian artery anastomoses is one of the fast, safe, effective and feasible hemostasis methods in cesarean section. The combination of the latter can block the uterine blood flow and further reduce the amount of intraoperative bleeding, especially for uterine body bleeding, which can be more rapid and effective hemostasis.

## Attachment Table

Table 1: PPH

## Reference

1. Committee on Practice Bulletins-Obstetrics. Practice bulletin no. 183: postpartum hemorrhage. *Obstet Gynecol.* 2017. 130: 168-186.
2. Making pregnancy safer. Geneva: World Health Organization. 2007.
3. Say L, Chou D, Gemmill A. Global causes of maternal death: a WHO systematic analysis. *Lancet Glob Health.* 2014. 2: 323-333.
4. Bienstock JL, Eke AC, Hueppchen NA. Postpartum Hemorrhage. *N Engl J Med.* 2021. 384: 1635-1645.
5. Say L, Chou D, Gemmill A. Global causes of maternal death: a WHO systematic analysis. *Lancet Glob Health.* 2014. 2: 323-333.

6. Mavrides E, Allard S, Chandraharan E, Collins P, Green L, et al. On behalf of the Royal College of Physicians. Prevention and management of postpartum haemorrhage. *BJOG*. 2016.
7. World Health Organization. WHO recommendations for the prevention and treatment of postpartum haemorrhage. Geneva: WHO. 2012.
8. Dobiesz VA, Robinson DW. Trauma in pregnancy. In: Walls RM, Hockberger R, Gausche-Hill M, eds. *Rosen's emergency medicine: concepts and clinical practice*. 9th ed. Philadelphia: Elsevier. 2017. 2314-22.
9. Bienstock JL, Eke AC, Hueppchen NA. Postpartum Hemorrhage. *N Engl J Med*. 2021. 384:1635-1645.
10. Leduc D, Senikas V, Lalonde AB, Ballerman C, Biringer A, et al. Clinical Practice Obstetrics Committee; Society of Obstetricians and Gynaecologists of Canada. Active management of the third stage of labour: prevention and treatment of postpartum hemorrhage. *SOGC Clinical Practice Guideline No. 235. J Obstet Gynaecol Can*. 2009. 31: 980-93.
11. Ostrowski P, Bonczar M, Michalczyk M, Gabryszuk K, Bereza T, et al. The anatomy of the uterine artery: A meta-analysis with implications for gynecological procedures. *Clin Anat*. 2023. 36: 457-464.
12. Li Jiafu. Prevention and treatment of bleeding after cesarean section by ligating the ascending branch of uterine artery [J]. *Chinese Journal of practical Gynecology and Obstetrics*. 2003. 17: 4151.
13. Su Yingkuan, Luan Mingzhen, Tang Chunsheng, et al. *Clinical Anatomy of Obstetrics and Gynecology [M]*. Jinan: Shandong Science and Technology Press. 2001.
14. Le Jie. *Obstetrics and Gynecology [M]*. Beijing: people's Health Publishing House. 2012.
15. Ge J, Liao H, Duan L, Wei Q, Zeng W. Uterine packing during cesarean section in the management of intractable hemorrhage in central placenta previa. *Arch Gynecol Obstet*. 2012. 285: 285-289.
16. Chen L, Wang X, Wang H, Li Q, Shan N, et al. Clinical evaluation of prophylactic abdominal aortic balloon occlusion in patients with placenta accreta: a systematic review and meta-analysis. *BMC Pregnancy Childbirth*. 2019. 19:30.
17. Mavrides E, Allard S, Chandraharan E, Collins P, Green L, Hunt BJ, Riris S, Thomson AJ on behalf of the Royal College of Obstetricians and Gynaecologists. Prevention and management of postpartum haemorrhage. *BJOG*. 2016. 124: 106-149.
18. Hunter LA. Exploring the role of uterine artery embolization in the management of postpartum hemorrhage. *J Perinatal Neonatal Nurs*. 2010. 24: 207-214.
19. Wu Hongyan, Hu Jing. Application of laparoscopic uterine artery combined with uterine and ovarian vascular occlusion in multiple myomectomies [J]. *Chinese Rural Medicine*. 2022. 29: 7-9.
20. Ouyang Zhenbo, Su Huanhuan, Zhang Qiushi. Anatomy and meaning of anastomotic branch of uterine artery and ovarian artery [J]. *China Maternal and Child Health*. 2014. 29: 3356-3358.