

# Giant Cell Tumor of the Flexor Sheath of the Index Finger

**Youssef El Hassnaoui\*, Tarik Mekdad, Abdelaziz EL Ansari, Hamza Madani, Issam Boulaazaib, Ait Benali Hicham, Shimi Mohammed.**

*Orthopedics and Trauma Surgery Department, Mohammed VI University Hospital Center Tangier, Faculty of Medicine and Pharmacy, Abdelmalek Essaadi University, Tangier, 90000, Morocco.*

## Corresponding author

El Hassnaoui Youssef, Orthopedics and Trauma Surgery Department, Mohammed VI University Hospital Center Tangier, Faculty of Medicine and Pharmacy, Abdelmalek Essaadi University, Tangier, 90000, Morocco.

**Received:** August 14, 2025; **Accepted:** August 22, 2025; **Published:** August 30, 2025

## ABSTRACT

Giant cell tumors (GCTs) of the tendon sheath are common benign neoplasms of the hand, arising from the synovial lining of tendon sheaths. We report the case of a 41-year-old man who presented with a painless mass on the right index finger, progressively enlarging over four years. Ultrasound examination revealed a well-circumscribed lesion consistent with a GCT. The patient underwent complete surgical excision without complications. At six-month follow-up, there was no evidence of recurrence. This case highlights the importance of early diagnosis and meticulous surgical management of this pathology.

**Keywords:** Giant Cell Tumor, Tendon Sheath, Flexor Tendon, Index Finger, Hand Surgery

## Introduction

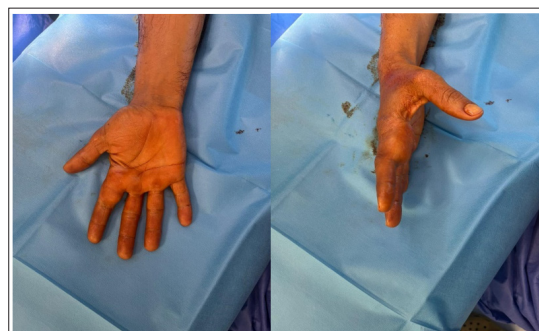Giant cell tumors (GCTs) of the tendon sheath, also known as localized nodular tenosynovitis, are the second most common benign tumors of the hand, following synovial cysts [1]. They typically arise slowly from the synovial lining of tendon sheaths and show a predilection for the palmar surface of the fingers [2]. Their progression is usually insidious, and they commonly present as a firm, painless, subcutaneous mass. Because they remain asymptomatic for an extended period, diagnosis is often delayed.

The diagnosis is primarily based on imaging studies, particularly ultrasound and magnetic resonance imaging (MRI), which allow for accurate assessment of the lesion's characteristics and anatomical location. Definitive confirmation relies on histopathological analysis, which establishes the benign nature and histological subtype of the tumor [3,4].

## Clinical Observation

A 41-year-old patient, with no previous medical history of note, presented with a painless mass on the right hand, which had been evolving for about four years. Clinical examination revealed

a firm swelling, mobile in relation to the superficial and deep planes, measuring 2 cm in its long axis. It is located opposite the metacarpophalangeal joint (MCP) of the second finger (index). The patient was afebrile and in good general condition. Finger mobility was preserved, with no pain or limitations. No local inflammatory signs or vascular nerve damage were observed (Figure 1).

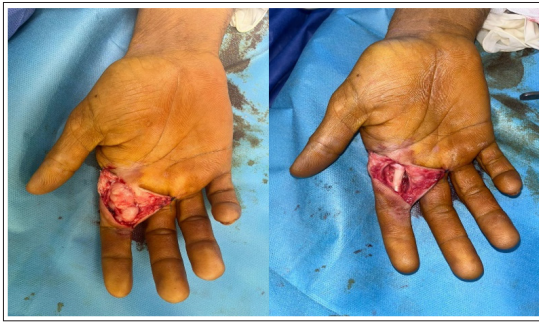

**Figure 1:** Clinical Appearance of Swelling Over the MCP Joint of the Second Finger.

An initial ultrasound of the soft tissue revealed a subcutaneous formation over the MCP joint of the 2<sup>nd</sup> finger, extending to the proximal interphalangeal joint. The lesion appeared oval,

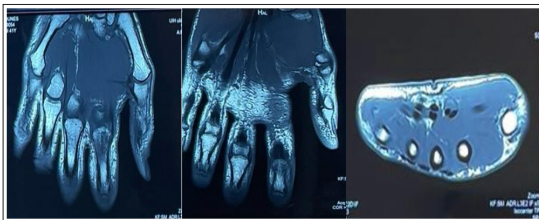
well-limited, lobulated, hypoechoic and heterogeneous, with no Doppler uptake. It measured approximately  $38 \times 17$  mm, noted that the flexor tendon was displaced in depth with no sign of rupture suggesting GCT.

A biopsy-exeresis was performed under locoregional anaesthesia (plexus block), using a palmar approach centred on the swelling via a zigzag incision. This allowed complete marginal removal of the tumour with release of the flexor tendon (Figure 2), followed by histological examination confirming a GCT with no sign of malignancy.



**Figure 2:** Surgical Excision Under Locoregional Anesthesia Using a Palmar Zig-Zag Approach to the Index Finger.

A follow-up MRI at 3 months post-op revealed inflammatory changes at the surgical site, with no evidence of tumor recurrence (Figure 3). At six-month follow-up, no recurrence was noted and finger function was normal.



**Figure 3:** Postoperative MRI Showing Inflammatory Changes at the Surgical Site with no Sign of Recurrence.

## Discussion

Tendon sheath GCTs are the second most common benign tumour of the hand, after synovial cysts [1]. They are localized benign proliferations, often regarded as a localized form of pigmented villonodular synovitis, due to their histopathological similarity [5].

They occur preferentially in women, between the ages of 30 and 50, with a predilection for the palmar surface of the 2nd and 3rd fingers [6]. Although the digital location is the most common, involvement of the foot, ankle and deeper joints has also been described [7].

Clinically, these tumors appear as firm, painless, well-limited subcutaneous masses. Their slow evolution often contributes to a delay in diagnosis. Depending on their location, they can restrict tendon mobility, although this is often preserved. Differential diagnoses include synovial cysts, lipomas, schwannomas or localized villonodular synovitis [4,8].

Ultrasound, the first-line examination for any digital soft tissue mass, generally shows a well-limited hypoechoic mass, sometimes lobulated, with little or no Doppler vascularization. It can be used to assess the relationship with the tendons, which are often repressed but intact, thus guiding the diagnosis and management of GCT [3].

MRI is the examination of choice for assessing lesion characteristics and their relationship to adjacent anatomical structures. GCTs classically present as well-circumscribed masses, in T1 and T2 hyposignal, with moderate post-gadolinium enhancement, related with the richness of histiocytic cells and hemosiderin deposits [9,10].

Histologically, they combine mononucleated cells, multinucleated osteoclastic giant cells, foamy macrophages, hemosiderin deposits and sometimes dense fibrous stroma [3,11]. Vascularization may be marked, sometimes explaining recurrence despite apparent complete excision. The absence of cellular atypia and abundant mitoses differentiates them from malignant tumors [5].

The gold standard of treatment remains complete surgical excision, often performed under a magnifying glass or operating microscope, to remove the entire tumour and reduce the risk of recurrence [12]. The risk of recurrence varies from series to series, ranging from 4% to 44%, and depends on location, tumour size and completeness of excision [2,6]. Proximity to neurovascular or articular structures sometimes complicates complete removal. Regular post-operative follow-up is essential to detect any recurrence. In our case, complete removal resulted in a favorable evolution without recurrence at six months. However, regular follow-up is essential, particularly in the first few years after surgery.

## Conclusion

Giant cell tumors of the tendon sheath are common benign lesions of the hand, characterized by a notable potential for local recurrence. Their management relies on high-resolution imaging, an accurate histopathological diagnosis, and complete surgical excision, which remains the only truly effective strategy to minimize the risk of recurrence. Rigorous postoperative follow-up is essential to detect any recurrence at an early stage and to adjust treatment accordingly.

## References

1. Adams EL, Yoder EM, Kasdan ML. Giant cell tumor of the tendon sheath: experience with 65 cases. *Eplasty*. 2012. 12: e50.
2. Hwang S, Kang HS, Kang HJ. MR imaging of giant cell tumor of the tendon sheath in the hand and foot. *Korean J Radiol*. 2007.
3. Middleton WD, Patel V, Teefey SA, Boyer MI. Giant cell tumors of the tendon sheath: analysis of sonographic findings. *AJR Am J Roentgenol*. 2004. 183: 337-339.
4. Al-Qattan MM. Giant cell tumours of tendon sheath: classification and recurrence rate. *J Hand Surg Br*. 2001. 26: 72-75.
5. Lucas DR. Tenosynovial giant cell tumor: case report with unusual features and literature review. *Arch Pathol Lab Med*. 2012.

6. Darwish FM, Haddad WH. Giant cell tumor of tendon sheath: experience with 52 cases. *Singapore Med J.* 2008. 49: 879-882.
7. Di Grazia S, Succi G, Fragetta F, Perrotta RE. Giant cell tumor of tendon sheath: a case report and review of the literature. *G Chir.* 2013.
8. Jaffe HL, Lichtenstein L, Sutro CJ. Pigmented villonodular synovitis, bursitis and tenosynovitis. *Arch Pathol.* 1941.
9. Beuckeleer LDe, Schepper A De, Belder F De, Van Goethem J, Marques MC, et al. Magnetic resonance imaging of localized giant cell tumour of the tendon sheath (nodular tenosynovitis). *Eur Radiol.* 1997. 7: 198-201.
10. Ushijima M, Hashimoto H, Tsuneyoshi M, Enjoji M. Giant cell tumor of the tendon sheath (nodular tenosynovitis): A study of 207 cases. *Cancer.* 1986. 57: 875-884.
11. Monaghan H, Salter DM, Al-Nafussi A. Giant cell tumour of tendon sheath: clinicopathological study of 71 cases. *J Clin Pathol.* 2001. 54: 404-407.
12. Kotwal PP, Gupta V, Malhotra R. Giant-cell tumour of the tendon sheath: Is radiotherapy indicated to prevent recurrence?. *J Bone Joint Surg Br.* 2000. 82: 836-839.