

Ruptured Ovarian Ectopic Pregnancy A Case Report from Leku General Hospital, Ethiopia

Asfaw Kibret

Department of Emergency Surgery, Leku General Hospital, Ethiopia

Corresponding author

Asfaw Kibret, Department of Emergency Surgery, Leku General Hospital, Ethiopia.

Received: May 04, 2025; Accepted: May 14, 2025; Published: May 22, 2025

ABSTRACT

An ovarian ectopic pregnancy is rare occurrence and it is implantation of trophoblastic tissue in or on the ovarian tissue. Most of the time delayed for diagnosis due to its resemblance on ultrasound as hemorrhagic ovarian cyst, hemorrhagic corpus luteum cyst or endometrioma. Usually it ruptures in the first trimester of pregnancy and due to its rich blood supply it is deadly hemorrhagic once it is ruptured. We present a 26yrs old para 2 mothers with the case of ruptured ovarian ectopic pregnancy who was diagnosed intraoperatively in our resource limited setup.

Keywords: Ectopic Pregnancy, Ovarian Ectopic Pregnancy, Corpus Luteum, Spiegelberg Criteria, Fallopian Tubes, Intrauterine Pregnancy

Introduction

An ectopic pregnancy is characterized by implantation and development of trophoblast tissue outside of the uterine cavity. The most common site for ectopic pregnancy is in the fallopian tube with the incidence being 95-97%. There are also other rare sites like, cervical, ovarian, peritoneal and hysterotomy scar [1,2].

Ovarian ectopic pregnancy is implantation in the ovarian tissue and it is the rarest entity of ectopic pregnancies with estimates of frequency ranging from 1 in 7000 to 1 in 40000 pregnancies or 0.3 -3% of all ectopic pregnancies. Traditional indicators of risk for ovarian ectopic pregnancy are similar to those for tubal pregnancy, however intrauterine devices appears and reported to be more strongly related [3,4].

Even If specific and typical features of ovarian ectopic pregnancy have not been reported, most cases presented with different duration of amenorrhea, lower abdominal pain and some present with spot vaginal bleeding. Once it is ruptured patients present with sudden hemodynamic deterioration. So early diagnosis and management saves once life.

Case Report

This is a 26yrs old para 2 mother who presented to our Leku general hospital with the complain of sudden lower abdominal pain, vomiting and unspecified syncope. She had regular menstrual cycle but she missed her last menses 6wks back. She has no hx of any contraceptive. She was complaining dull aching intermittent pelvic pain for last 1week. Currently the pain was persistent and with sudden syncope. At presentation she was in shock with Blood pressure of 80/50mmgh, she was tachycardic with heart rate 110bpm. She had moderately pale conjunctiva. In the emergency department fluid resuscitation started and Investigation sent. Laboratory revealed with positive urine HCG, hematocrit 20.4% and blood group was B+ve. For this gynecological unit of the hospital was consulted and transabdominal ultrasound was done which revealed empty uterus, massive pelvic collection Lt side adnexal heterogeneous and anechoic collection. With impression of ruptured ectopic pregnancy, she had been taken to operation theater and general anesthesia given and via the Pfannenstiel like incision abdomen opened, there was around 1200ml hemoperitoneum. The fallopian tubes were quite healthy looking. There was active bleeding from left ovary which is with ruptured ectopic and near to abort conceptus tissue from the ovary, later histopathology confirmed ovarian pregnancy (fig.1). Left side oophorectomy was done since the patient was hemodynamically unstable and there was multiple oozers from the left ovary. Intraoperatively

Citation: Asfaw Kibret. Ruptured Ovarian Ectopic Pregnancy A Case Report from Leku General Hospital, Ethiopia. J Clin Med Health Care. 2025. 2(2): 1-3.

DOI: doi.org/10.61440/JCMHC.2025.v2.20

after hemostasis secured, 1 unit blood transfusion started. Patient awake, extubated and transferred to recovery unit. Her post operative stay was uneventful and discharged on the 3rd day. On follow up appointment she visited the gynecologic clinic in stable condition.

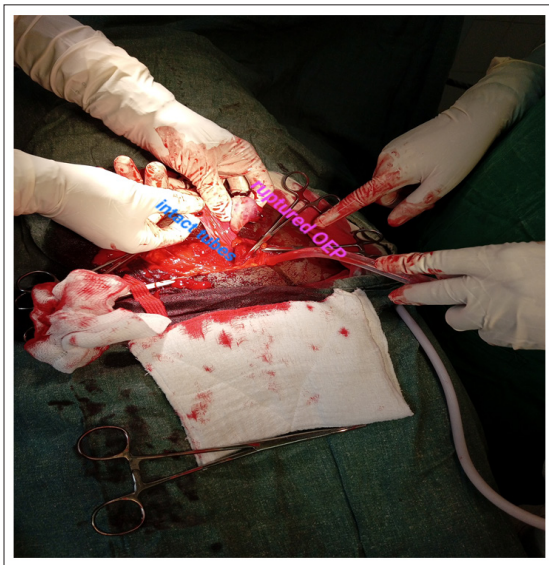


Figure 1: Intraoperative Picture of Ruptured Left Ovarian Ectopic Pregnancy

Discussion

Primary ovarian pregnancy is one of the rarest extra uterine pregnancy. The incidence of ovarian ectopic pregnancies has increased over the past decades from 0.7% to 1 of all ectopic pregnancies in the 1950s to up to 3.5% in recent studies. There are two types of ovarian ectopic pregnancies; 1-Intrafollicular ovarian pregnancy when the ovum remains trapped within the follicle and fertilization occurs within the follicle and not expelled. 2-Extrafollicular ovarian pregnancy when the mature ovum is fertilized outside the ovary and implants on its surface. According to systematic reviews ovarian pregnancies seem to be associated with similar causal factors as extra uterine pregnancies, such as PID, IVF, previous ectopic pregnancy, intrauterine devices or tubal surgery however intrauterine devices (IUDs) appears to be more strongly related [4,5].

The exact cause of implantation in the ovarian ectopic pregnancies is uncertain, but several hypotheses have been proposed: 1, delayed ovum release 2, thickening of the tunica albuginea 3, tubal dysfunction 4, use of IUDs. are among the few to mention. Thinking of these, researches suggest and tried to mention two hypothesis and attempt to explain the cause under this hypothesis. One theory suggests fertilization occurs normally and the fertilized egg then reflexes from the fallopian tube to the ovary, where it implants. The alternative hypothesis proposes the egg is fertilized within the ovarian follicle before it is released, leading to implantation on the ovary [4,6].

Mostly patients of ectopic pregnancy comes with triad of delayed menstruation, pain, vaginal bleeding or spotting and a positive pregnancy test. however, only 50% of patients present with typical symptomatology. Mostly before rupture of the ectopic pregnancy, the ovarian ectopic pregnancies are delayed in diagnosis and missed than the tubal ectopic pregnancies. Because

the gestational sac of an ovarian ectopic pregnancy resembles a hemorrhagic corpus luteum cyst or ovarian endometrioma or other hemorrhagic simple ovarian cysts on ultrasound. So high level suspicion is mandatory in these types of cases. Most of the time ovarian ectopic pregnancy is diagnosed intraoperatively. There is Spiegelberg's criteria which rely on intraoperative findings and include; 1-an intact fallopian tube on the involved side; 2-the gestational sac within the ovary; 3-the ovary attached to the utero-ovarian ligament and 4-on histological examination the ovarian tissue present in the wall of the gestational sac [7,8].

The preoperative diagnosis of an ovarian ectopic pregnancy can be difficult because the symptoms are not specific and the ultrasound diagnosis is also difficult where there is no advanced ultrasound is available in most resource limited areas like our setups.

Usually ovarian ectopic pregnancy rupture in the 1st trimester of pregnancy and it is associated with significant maternal morbidity and mortality, due to the risk of internal hemorrhage and hemodynamic instability. Since the ovarian tissue is rich in blood supply, it can lead to deadly hemorrhage once the ovarian ectopic pregnancy is ruptured [6].

Surgical management is the treatment choice in the case of ovarian ectopic pregnancies. Open surgery is still comes the first hand in most resource limited areas like our setup. If ovarian ectopic has been diagnosed the management may include Salpingo-oophorectomy, oophorectomy, wedge resection, and removal of gestational product with ovarian tissue preservation [9,10].

Conclusion

Even if ovarian ectopic pregnancy is rare entity, it can present with deadly maternal mortality morbidity unless managed early. The first thing in the management of ovarian ectopic pregnancy is securing hemostasis but if it is possible preserving the fertility by ovarian preservation surgeries like wedge resection of ovary will be grateful for those who have a plan for more birth. Early detection and appropriate management are critical to prevent life-threatening complications.

Acknowledgement: Great appreciation and appraisal for all staffs who are involved in the management of the case.

Fund: No Fund

Conflict of Interest: None

Ethical Approval: We have obtained written informed consent for publication from the patient.

References

1. Jayson JA, Mandrelle K, Chander A, Issacs R. Case report of ruptured ovarian ectopic pregnancy. *Int J Reprod Contracept Obstet Gynecol.* 2022. 11: 1779-1781.
2. Kibret A, Adisu A, Zekarias Z, Tesema D, Alemayehu H, et al. Ruptured Tubal Stump Ectopic Pregnancy After Previous Ipsilateral Salpingectomy: A Case Report and Literature Review, *Clinical Case Reports and Studies, BioRes Scientia Publishers.* 2024. 7: 1-3.

3. Johnston B. Ovarian pregnancy in association with a Copper 7 intrauterine contraceptive device. *J R Army Med Corps.* 1987. 133: 94-95
4. Elizabeth K, Venugopal A. A case report of ruptured ovarian ectopic pregnancy. *Int J Reprod Contracept Obstet Gynecol.* 2024. 13: 2529.
5. Tehrani HG, Hamoush Z, Ghasemi M, Hashemi L. Ovarian ectopic pregnancy: a rare case. *Iran J Reprod Med.* 2014. 12: 281.
6. Solangon SA, Naftalin J, Jurkovic D. Ovarian ectopic pregnancy: clinical characteristics, ultrasound diagnosis and management. *Ultrasound Obstet Gynecol.* 2024. 63: 815-23.
7. Bouab M, Touimi AB, Jalal M, Lamrissi A, Fichtali K, Bouhya S. Diagnosis and management of ectopic ovarian pregnancy: a rare case report. *Int J Surg Case Rep.* 2022. 91: 106742.
8. Van Mello NM, Mol F, Opmeer BC, W M Ankum, K Barnhart, et al. Diagnostic value of serum hCG on the outcome of pregnancy of unknown location: a systematic review and meta-analysis. *Hum Reprod Update.* 2012. 18: 603-617.
9. Al-Dabal HJ, Al Zahrani M, Al Rabiah HA, Khan L. Ovarian Ectopic Pregnancy: A Case Report. *J Med Case Rep Case Series.* 2022. 5: 1-4.
10. Meena P, Bhojwani P, Verma GS. Ovarian ectopic pregnancy: a case report with review of literature. *Obs Rev: J obstet Gynecol.* 2017. 3: 25-32.